

## Case Report

### Abdominal actinomycosis simulating chronic appendicitis: A case report

<sup>1</sup>Dr. Vidya Rekha R Kamath , <sup>2</sup>Dr. Kishan Prasad H.L, <sup>3</sup>Dr. Abhijith Shetty \* , <sup>4</sup>Dr. Jayaprakash Shetty K, <sup>5</sup>Dr. Aashish Sharma K

<sup>1</sup>Post graduate , <sup>2</sup>Professor , <sup>3</sup>Assistant Professor\*, <sup>4</sup>Professor , <sup>5</sup>Post graduate

Department of Pathology, Department of Surgery \* . K S Hegde Medical Academy, Mangalore, Karnataka, India.

Corresponding author: Dr. Vidya Rekha R Kamath, Post graduate, Department of Pathology, K S Hegde Medical Academy, Deralakatte, Mangalore, Karnataka, India.

#### Abstract

The appendix is a relatively small anatomic compartment with the diversity of pathologic processes that may arise from it. Appendicitis is the most common entity in the appendix. Appendicular actinomycosis is rare, but it can occur. This report describes a 32-year-old female who underwent appendectomy for chronic appendicitis and was found to have actinomycosis on histopathological examination. She underwent treatment with antibiotics. On follow up, the patient has been doing well in the last two years.

**Key words:** actinomycosis, appendicitis, histopathology.

#### Introduction

Actinomycosis is a chronic granulomatous disease caused by filamentous, gram-positive, anaerobic bacteria. Actinomycosis has a worldwide distribution and, most commonly affects middle-aged individuals. Men are more affected than women. Actinomyces species are an endogenous flora present in the mucous membranes of the gastrointestinal, respiratory, and genital tracts and cause a disease referred to as actinomycosis. Actinomycosis develops when mucosal barriers are breached and these bacteria gain access to deeper tissues. <sup>1</sup> Abdominal actinomycosis is a rare disease that mimics several other diseases and requires accurate diagnosis. The most commonly involved regions are cervicofacial, thoracic, abdominopelvic and cerebral. Abdominal actinomycosis is less common (approximately 20% of cases) and has a predilection for the terminal ileum, cecum and appendix. The most common presentation of appendiceal actinomycosis is acute, mimicking acute appendicitis. <sup>2</sup>

#### Case Report

A 32 year old female, presented with right iliac fossa pain since 2 days. Abdominal pain has been recurrent for 2 months. On physical examination, her pulse rate was 96 beats/ min, her body temperature was 37.4°C, and she had tenderness and rebound pain in the right lower quadrant of the abdomen. Cardiovascular system and respiratory system examination were unremarkable. Hematological parameters showed an increasing total leukocyte count. Serological tests were unremarkable. Ultrasound abdomen suggested provisional diagnosis of acute inflamed appendix. Hence, an emergency appendectomy was performed.

#### Histopathology

On gross examination of appendectomy specimen measured 3.5 cms in length. The outer surface was congested. Appendicular tip was thickened. The cut surface revealed patent lumen and presence of faecolith.

Microscopic sections studied shows appendix with thickened wall with fibrosis, dense hyperplastic lymphoid follicles. Mucosa is ulcerated and lined by granulation tissue (Figure 1). The lumen contains exudative material containing actinomycotic colonies (Figure 2). Serosa shows congested blood vessels. Suggesting acute on chronic appendicitis with actinomycosis.

She was started on high-dose parenteral administration of penicillin G for two weeks immediately after the diagnosis and continued oral penicillin G for the next 6 months. With regular follow up, the patient is doing well without any fresh complaints.

### **Discussion**

Actinomycosis is a rare, chronic, progressive disease characterized by the formation of abscesses, draining sinuses, granulation and tissue fibrosis. Abdominal actinomycosis is common and accounts for approximately 20% of cases.<sup>2</sup> The disease is caused by non-spore-forming, anaerobic, Gram-positive bacterial species of Actinomyces, mostly *A. israelii*, which is a saprophyte and have usually a low pathogenicity. The disease develops only in the setting of tissue injury like penetrating trauma, perforation of the intestine, or surgical manipulation.

The histological hallmark is the presence of “sulfur-granules” that are commonly considered diagnostic of actinomycotic infection, but are present in only 50% of cases. The most common presentation of abdominal actinomycosis is acute, and the differential diagnosis includes acute appendicitis, Crohn’s disease, or colon tumor.<sup>3</sup>

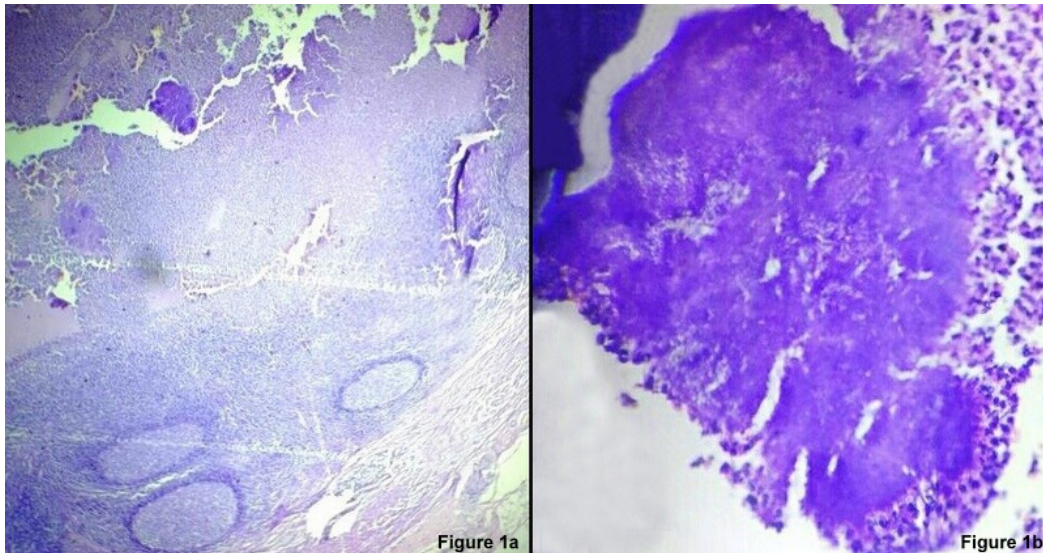
Abdominal actinomycosis poses great challenges in diagnosis. It has been called “one of the greatest imitators in clinical practice”. It is uncommon and accounts for 20% of actinomycosis infection. It presents as an indolent chronic suppurative process with atypical symptoms that are often misinterpreted. The appendix is the most frequently involved organ, which once ruptured stimulates pathologic growth of these organisms and causes right- sided symptoms.<sup>4</sup> Abdominal actinomycosis is usually preceded by events or conditions (gastrointestinal surgery, diverticulitis, appendicitis, the presence of a foreign body) that occurred weeks to months earlier and that resulted in the loss of mucosal integrity. Because actinomycosis of the appendix is a rare event, it can easily be misdiagnosed and may become disseminated months or years after appendectomy.<sup>1</sup> A combination of adequate surgery and long-term antibiotic therapy should be carried out to achieve the complete eradication of actinomycosis. Although the surgical treatment facilitates recovery, it is usually not curative. Prolonged observation is necessary after the treatment to detect recurrences.<sup>5,6</sup>

### **Conclusion**

The appendix is often a nidus of Actinomyces infection, but a prompt diagnosis can be difficult. In most cases, the diagnosis is often possible after surgical exploration and therefore the treatment becomes complex.

Figure 1a: Microscopy of Acute on chronic appendicitis (H&E X 40)

Figure 1b: Microscopy shows actinomycosis colonies (H&E X 400)



**References:**

1. Russo AT. Agents of actinomycosis. In: Mandell GL, Douglas RG, Bennet JE, Dolin R, editors. Mandell, Douglas, and Bennett's principles and practice of infectious diseases. 6th ed. Philadelphia (PA): Elsevier Churchill Livingstone; 2005. p. 2925-34.
2. Paritsky M, Cherepnin L. Abdominal actinomycosis mimicking chronic appendicitis. J Clin Case Rep. 2012; 2(14):208.
3. Garner JP, Macdonald M, Kumar PK. Abdominal actinomycosis. Int J Surg. 2007; 5: 441-48.
4. Sumer Y, Yilmaz B, Emre B, Ugur C. Abdominal mass secondary to actinomyces infection: An unusual presentation and its treatment. J Postgrad Med. 2004; 50 (2):115-17.
5. Meyer P, Nwariaku O, McClelland RN, Gibbons D, Leach F, Sagalowsky AI, et al. Rare presentation of actinomycosis as an abdominal mass: report of a case. Dis Colon Rectum. 2000; 43:872-5.
6. Karagulle E, Turan H, Turk E, Kiyici H, Yildirim E. Abdominal actinomycosis mimicking acute appendicitis. Can J Surg. 2008; 51: 109-10.